DISORDERS AND CONDITIONS OF THE EYE

TITUS K. LEKIRRIE

BscN.

– Housed in a cone of fatty tissue

Eyeball

– Three layers
– External fibrous layer
– Middle vascular layer
– Inner layer of nerve tissue

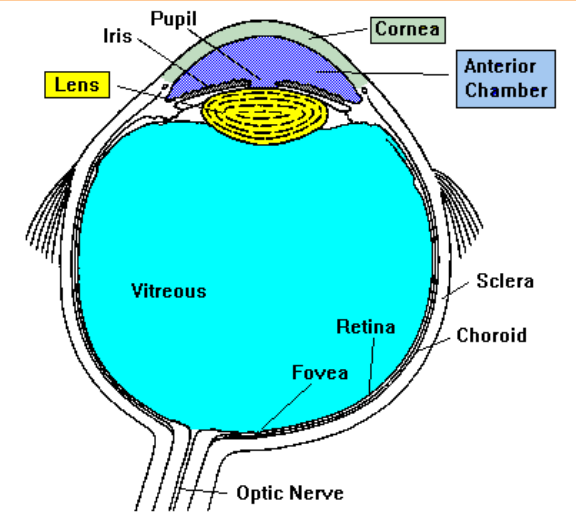

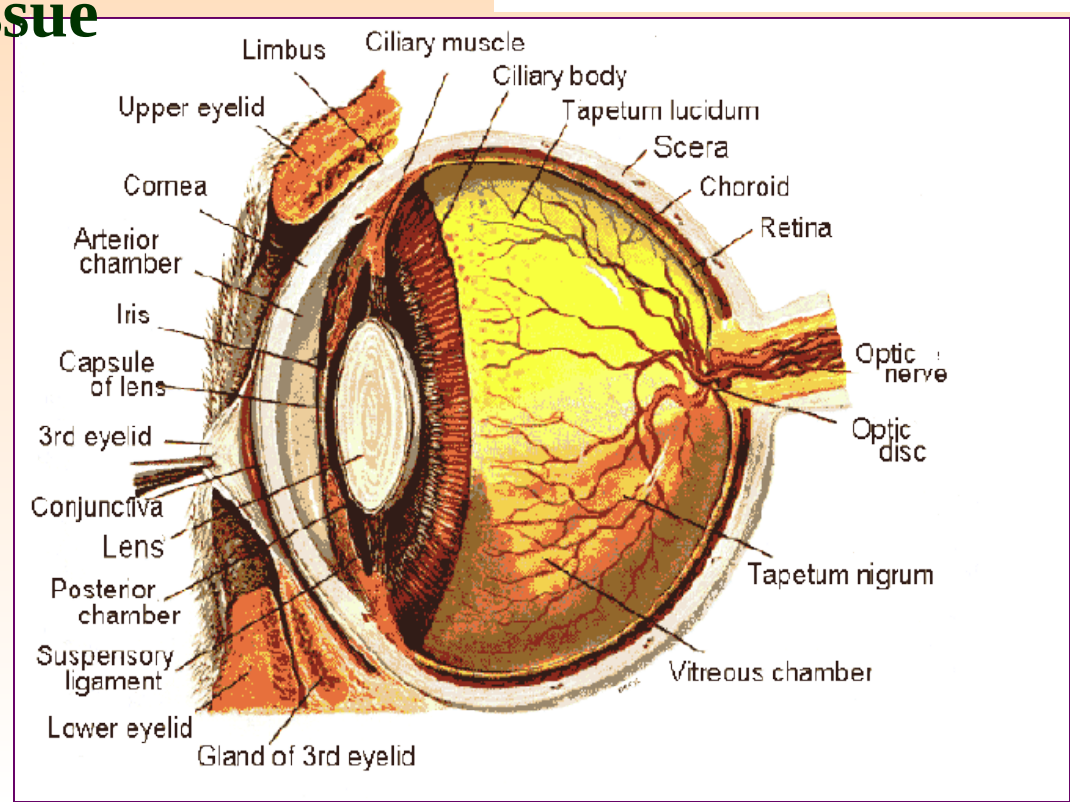

✡■❀▼❑○❙ ❑❄ ▼❊❄ ✣❙❄

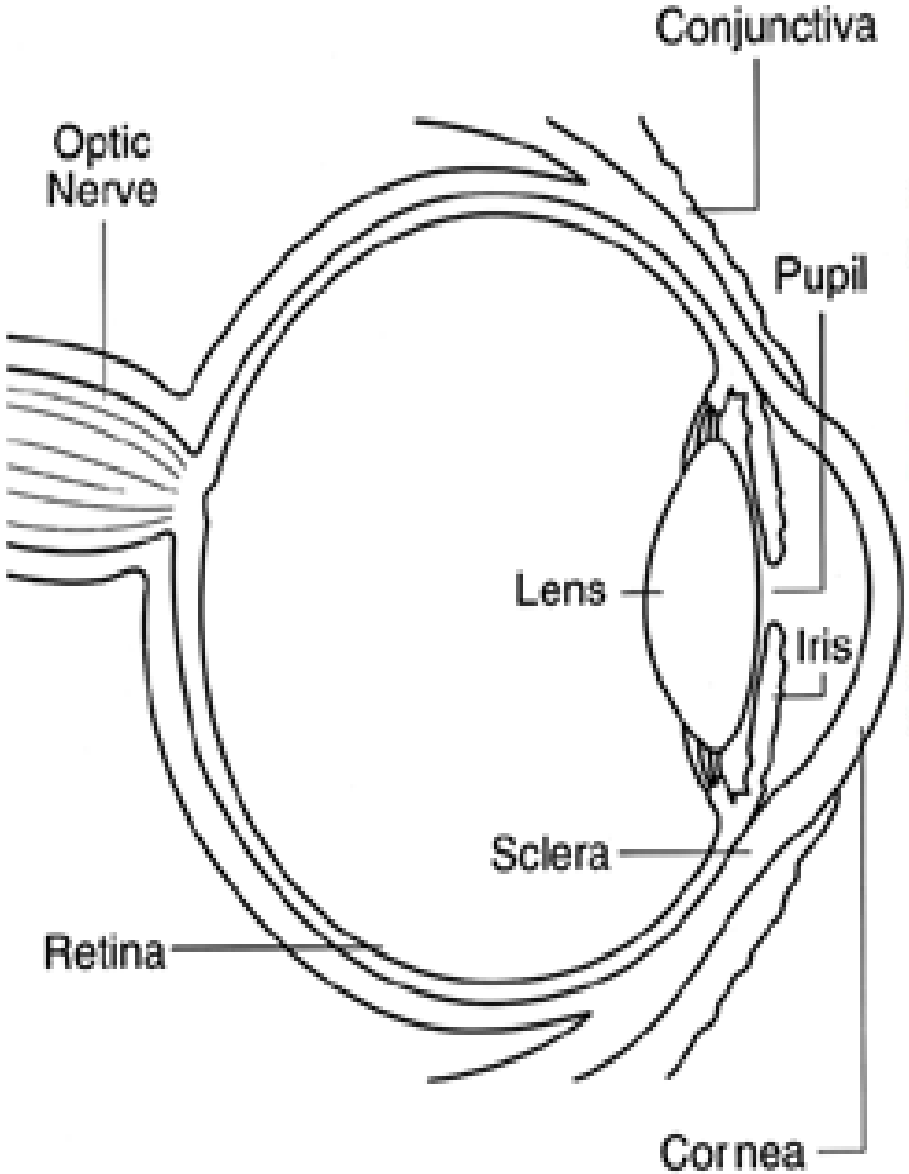
Conjunctiva
Optic Nerve
Pupil
Lens
Iris
Sclera
Retina
Cornea

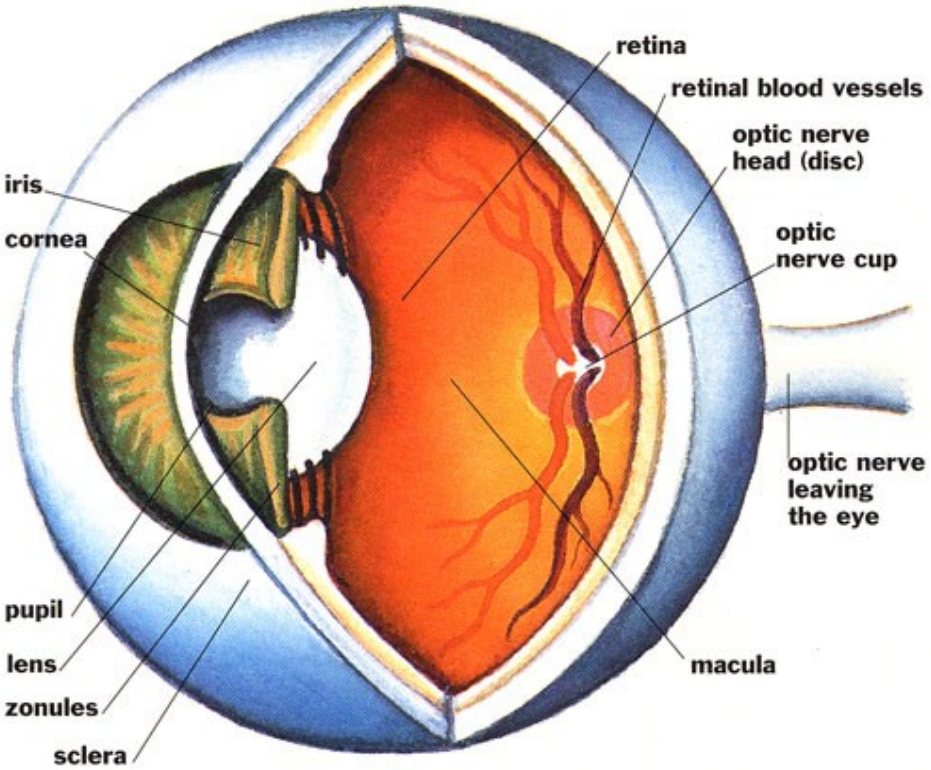
retina
retinal blood vessels
optic nerve head (disc)
iris
cornea
optic nerve cup
optic nerve leaving the eye
pupil
lens
zonules
sclera
macula

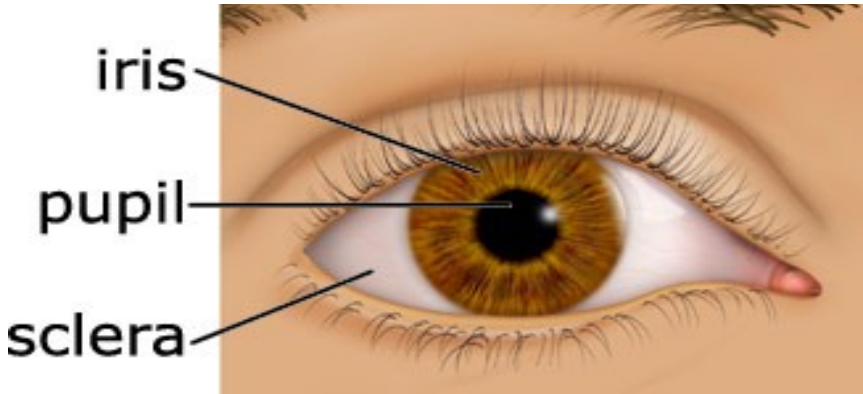
iris
pupil
sclera

- **Sclera**
  - **“white of eye’**
    - **Protective & supportive outer layer**
- **Cornea**
  - **Dense fibrous connective tissue**
    - **Must be transparent to allow light**

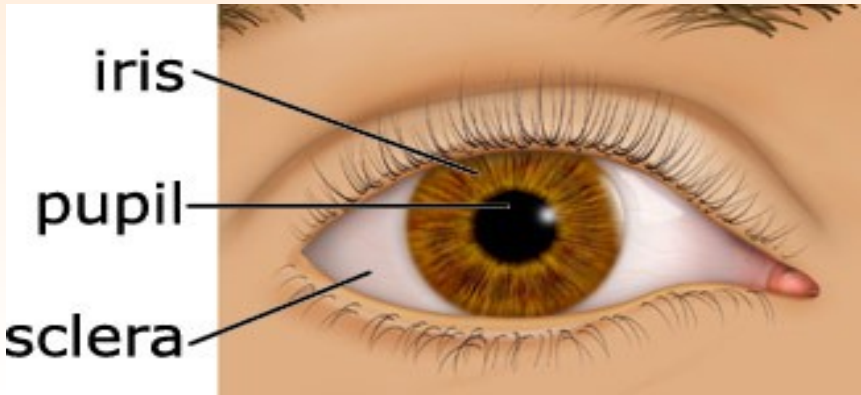

- **Heavily pigmented**
- **Blood vessels**

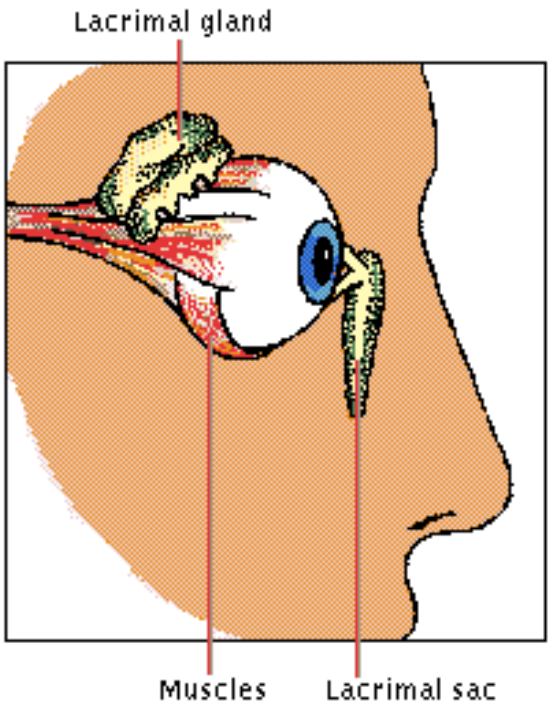

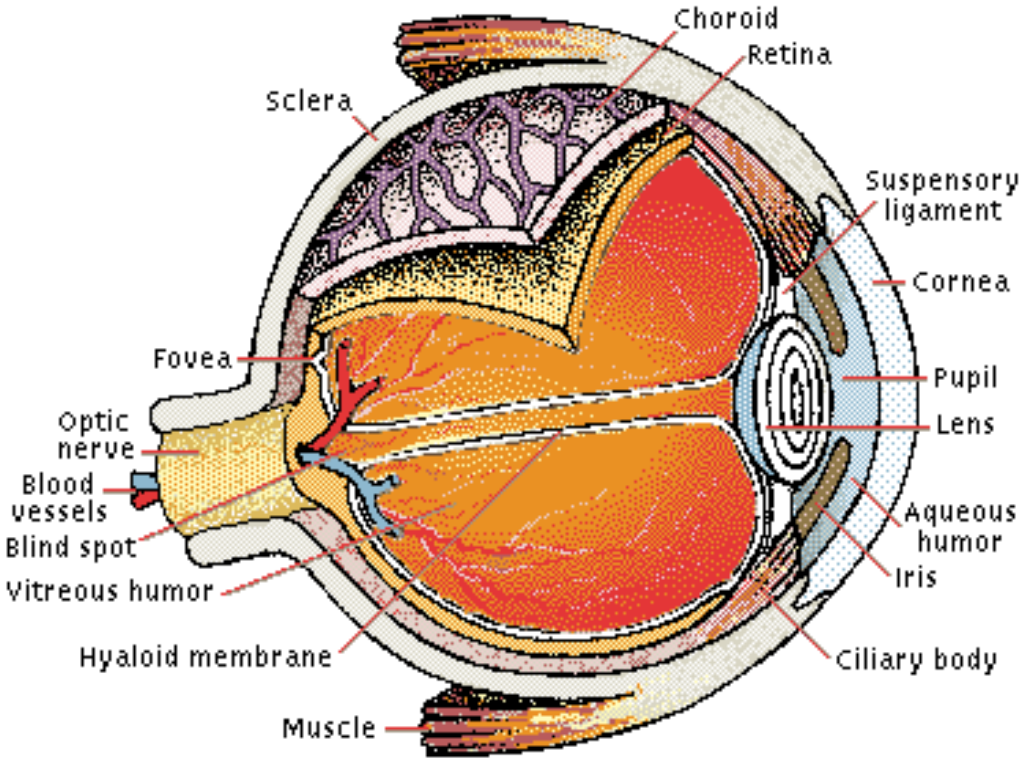

- **Retina**
  - Continuous with optical nerve in rear
  - Ora serrata in front
  - Two parts
    - Outer part-pigmented-attached to choroid layer
    - Inner part is nerve tissue

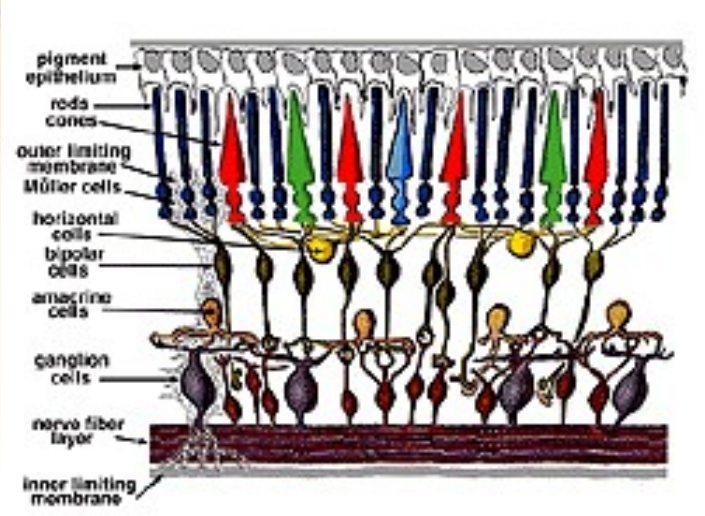

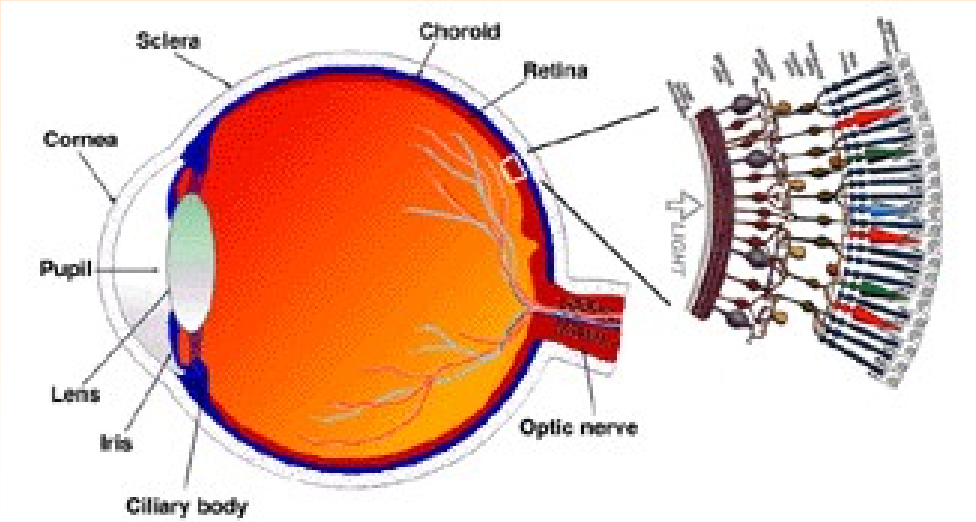

- Eyelids
  - Tarsal glands secrete oil to lubricate
- Lacrimal glands – outer edge of eye socket
  - Secretes tears to clean & protect
- Aqueous humor – between cornea & lens
  - Salty clear fluid

- Thin membrane lining rear of eye
- Contains light sensitive cells
- Rods & cones
  - Rods are sensitive to light
    - 120 million rods
  - Cones are sensitive to colors
    - 6 million cones

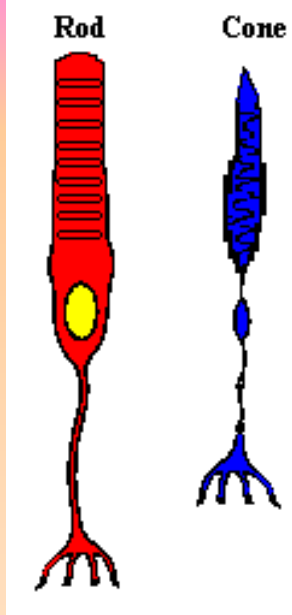



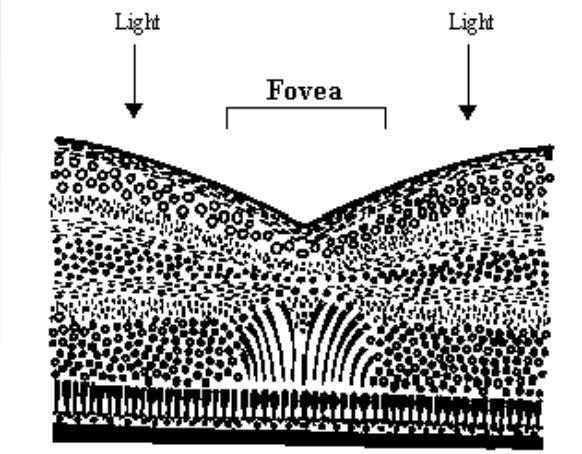

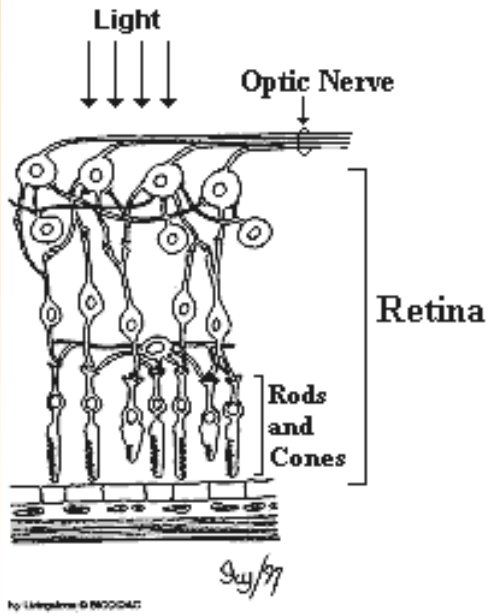

- **History taking**

➢ Visual loss or discomfort

➢ Poor vision

➢ Medical conditions e.g HTN, DM

➢ Drugs e.g chlorouine,isoniazid

➢ Family Hx. E.g retinitis, glaucoma

➢ Allergies & infections eg conjunctivitis.

Cont…

- Sudden visual loss…optic nerve
- Retinal abnormalities i.e total occlusion of central vein
- Optic nerve abnormalities i.e demyelination of optic nerve

- **Examination**
  - Both structure and function are examined**.**

Physiologic examination.

- **Visual Acuity**
- **Visual fields**
- **IntraOccular pressure**

- Tests visual resolving power of the eye.
- Snellen chart
- Acuity..reading distance over row number of smallest number seen e.g 6meters
- Cardiff Acuity test for 1-3 years.
- Sheridan-Gardiner test for older children.

- Snellen Chart

- Maps peripheral extend of the visual world.
- Blindspot..no photoreceptors
- VF is tested through;

a. Confrontation tests- comparison of VF of examiner & patient.

b. Perimeter machine- tests kinetic and static VF.

- Measured by contact technique using Goldmann tonometer.
- Plastic cylinder pressed against anaesthetized cornea.
- Force applied to cylinder varies to alter amount of corneal flattening.

While some individuals show pupil asymmetry unassociated with disease, remember that inflammation of the anterior segment (*iritis*), trauma or previ-

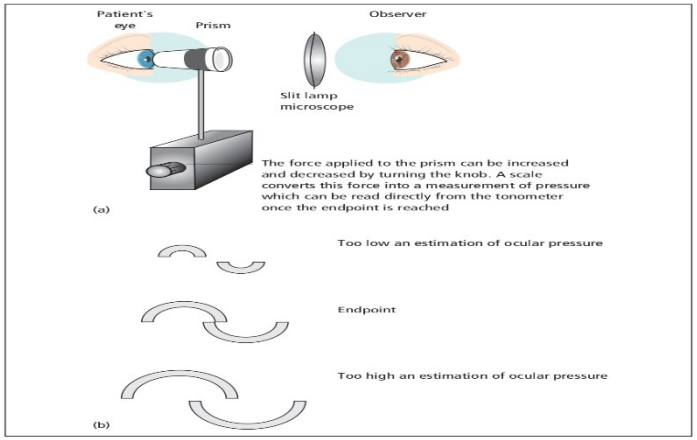

Figure 2.4 (a) Measurement of intraocular pressure with a Goldmann tonometer. (b) Two hemicircles are seen by the examiner. The force of contact is increased until the inner borders of the hemicircles just touch. This is the endpoint, at which a fixed amount of flattening of the cornea is achieved.

ous ocular surgery may cause structural iris changes which mechanically alter pupil shape or result in posterior synechiae (see Chapter 9).

Where the pupil sizes are equal, in order to test the efferent limb of the pupil reflex, the patient is asked to look at a near object. Normal pupils constrict in

n can be increased
e knob. A scale
asurement of pressure
om the tonometer
l

ation of ocular pressure

nation of ocular pressure

- REFRACTIVE ERRORS
- MUSCULAR DISORDERS
- DISORDERS OF THE EYELID
- DISORDERS OF THE GLOBE OF THE EYE

- **REFRACTIVE ERRORS**

- ***HYPEROPIA.***
- ***MYOPIA.***
- **ASTIGMATISM**
- ***PRESBYOPIA***

HYPEROPIA (FAR SIGHTEDNESS)

- ***MECHANISM***
  - **** object focuses behind the retina***
    **** able to see only far objects***
- ***ETIOLOGY***
  - **** genetic link***

- **SYMPTOMS AND SIGNS**
  - *** blurred vision**
    *** squinting**
    *** eye rubbing**
    *** headaches**
- **DIAGNOSIS**
  - *** Snellen visual acuity test**
  - *** ophthalmoscope**
- **TREATMENT**
  - *** Convex lens**

MYOPIA (NEAR SIGHTEDNESS)

- **MECHANISM**
  - * object focuses in front of the retina
    * able to see only close objects
- **ETIOLOGY**
  - * genetic link
- **SYMPTOMS AND SIGNS**
  - * blurred vision
    * squinting
    * eye rubbing* headaches

- ***DIAGNOSIS***
  - * Snellen visual acuity test
    * opthalmoscope
- ***TREATMENT***
  - * concave lens
    * radical keratotomy - shallow incision in the cornea causing it to flatten in desired area (could have significant complications)

ASTIGMATISM

- **MECHANISM**
  - * Abnormal shaped cornea
    (egg shape instead of spherical)
    * object is partially clear & other blurred
- **ETIOLOGY**
  - * genetic link

- **SYMPTOMS AND SIGNS**
  - *** blurred vision**
    *** squinting**
    *** eye rubbing**
    *** headaches**
- **DIAGNOSIS**
  - *** Snellen visual acuity test**
    *** opthalmoscope**
- **TREATMENT**
  - *** artificial lens transplan * radial keratotomy**

PRESBYOPIA

- **MECHANISM**
  - *** Rigidity of the lens (old age)**
    *** unable to focus**
- **ETIOLOGY**
  - *** genetic link**
- **SYMPTOMS AND SIGNS**
  - *** blurred vision**
    *** squinting**
    *** eye rubbing**
    *** headaches**

- **DIAGNOSIS**
  - * Snellen visual acuity test
    * opthalmoscope
- **TREATMENT**
  - * lens transplant

MUSCULAR DISORDERS

- NYSTAGMUS
- STRABISMUS (CROSS EYED)

NYSTAGMUS

- **MECHANISM**

* repetitive involuntary movements of one or both eyes

- **ETIOLOGY**

* Congenital
* Brain tumors
* CV lesions
* Ear lesions
* Alcohol/drug abuse

- **SYMPTOMS AND SIGNS**
  - * **<u>Eye Movements</u>**

    *Horizontal, vertical, circular, or combination

    * blurred vision
- **DIAGNOSIS**

  * viewing of the eyes - involuntary movement

  * complete neurological tests
- **TREATMENT**

  * Treat the underlying condition

  * Congenital stays for life

STRABISMUS (CROSS EYED)

- **MECHANISM**
  - * Failure of eyes to look in the same direction at the same time
    * Weakness of muscles of one eye
    (superior oblique, interior oblique, lateral)
- **ETIOLOGY**
  - in <u>childhood</u>: associated with amblyopia (decreased vision in one eye)
    (reversible after 7 years of age)
    in <u>adults:</u> Usually caused by disease:
    i.e. diabetes, high blood pressure, brain trauma

- **SYMPTOMS AND SIGNS**
  - * **<u>TYPES:</u>**

    1. **Esotropia** (convergent-cross eye of one eye)
    2. **Exotropia** (divergent- one eye turns outward)
    3. **Diplopia** (adults strabismus)
    4. **Congenital** (no strabismus exists)

- **DIAGNOSIS**
  - * complete ophthalmic examination
    * Diagnose underlying disease
- **TREATMENT**
  - * Treat early
    * Corrective glasses
    * orthoptic training
    * surgery to restore eye muscle balance
    * treat underlying disorder

DISORDERS OF THE EYE LID

- HORDEOLUM (STYE)
- CHALAZION (MEIBOMIAN CYST)
- BLEPHARITIS
- ENTROPION
- ECTROPON
- CONJUNCTIVITIS (PINK EYE)

HORDEOLUM (STYE)

- **MECHANISM**
  - * Inflammatory infection of the hair follicle of the eye lid
- **ETIOLOGY**
  - * staphylococcal infection
    * usually associated with Blepharitis
- **SYMPTOMS AND SIGNS**
  - * occurs on the outside
    * Pain/swelling/redness/pus
    * patient feels something in the eye

- **DIAGNOSIS**
  - *** Visual exam**
    *** culture if needed**
- **TREATMENT**
  - *** Hot compress to alleviate pain**
    *** Topical or systemic antibiotics**

CHALAZION (MEIBOMIAN CYST)

- **MECHANISM**
  - * Collection of fluid or soft mass cyst
- **ETIOLOGY**
  - * Blockage of meibomian gland
- **SYMPTOMS AND SIGNS**
  - * Pea size cyst
    * painless slow swelling of the inner part of eye lid
    * Could become infected

- **DIAGNOSIS**
  - * Visual Examination
- **TREATMENT**
  - * small ones usually disappear spontaneously after a month or two
    * large ones usually need surgical removal

BLEPHARITIS

- **MECHANISM**
  - * Inflammation of the margins of the eye lids
- **ETIOLOGY**
  - * Ulcerative: staphy infection
    * nonulcerative: allergies, smoke, dust, chemicals, seborrhea, stye, chalazions
- **SYMPTOMS AND SIGNS**
  - * Persistent redness & crusting on eyelids
    * itching / burning sensation
    * feeling something in the eye
    * Ulcers can cause eye lashes to fall out
    * Scales can get into eye causing conjunctivitis

- **DIAGNOSIS**
  - * visual examination
    * Culture (confirm staphy infection)
- **TREATMENT**
  - * Salt & water cleansing for 2 weeks
    * If unsuccessful - local antibiotics or sulfonamide

ENTROPION

- **MECHANISM**
  - * Inversion of eye lid into eye
- **ETIOLOGY**
  - * aging (course fibrous tissue)
- **SYMPTOMS AND SIGNS**
  - * Foreign body sensation
    * Tearing / itching / redness
    * Continuous rubbing causes conjunctivitis or corneal ulcers
    * Decreased visual acuity if not corrected

- **DIAGNOSIS**
  - *** visual examination**
- **TREATMENT**
  - *** clean up on its own**
    *** if not, minor surgery**

ECTROPON

- **MECHANISM**
  - * Outurned eye lids
- **ETIOLOGY**
  - * elderly (weakness of eye lid muscles)
- **SYMPTOMS AND SIGNS**
  - * dryness of the exposed part of the eye
    * tears run down the cheeks
    * if not treated can cause ulcers and permanent damage to cornea

- **DIAGNOSIS**
  - * visual examination
- **TREATMENT**
  - * minor surgery if doesn’t disappear

BLEPHAROPTOSIS (PTOSIS)

- **MECHANISM**
  - * weakness of eye muscle that raises eyelid (superior rectus, superior oblique)
- **ETIOLOGY**
  - * familial
  - * trauma
    * diabetes mellitus
  - * muscular dystrophy
    * myasthenia gravis
  - * brain tumors

- **SYMPTOMS AND SIGNS**
  - * “drooping eye”
    * Blocks vision
- **DIAGNOSIS**
  - * ophthalmic examination
    * blood work to rule out underlying disease
- **TREATMENT**
  - * Surgery (strengthen muscles)
    * eye glasses with raised eyelid support
    * treat underlying disease

CONJUNCTIVITIS (PINK EYE)

- **MECHANISM**
  - * inflammation of the conjunctiva
- **ETIOLOGY**
  - * Viral / bacterial
    * irritants (allergies, chemicals, UV light)
- **SYMPTOMS AND SIGNS**
  - * Redness / swelling / itching
    * tearing when exposed to light
    * pus if infectious
    * “contagious” with contaminated hands, washcloths

DIAGNOSIS

- Ophthalmic examination
- Culture discharge

TREATMENT

- Warm compress 3-4 times daily (10-15 min.)
- If bacterial (antibiotics)
- If viral- self limiting

- **STEP ONE:**
  Tilt your head back. Using your middle finger, gently press the corner of the eye by the side of the nose.

- **STEP TWO:**
  Use your index finger to pull down the lower lid. Then apply the eye drop medicine.

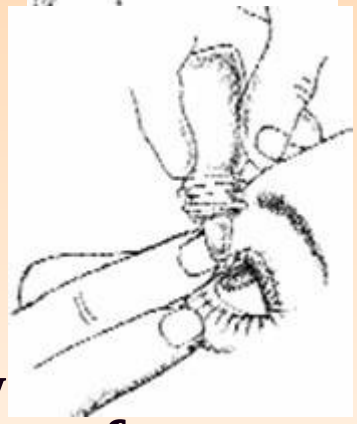

- **STEP THREE:**
  After applying the eye drop, let go of your low
  Close the eye and keep the middle finger in place for at least two minutes. If you're applying more than one type of drop, wait at least 15 minutes for the next application. Use a facial tissue to wipe away excess drops on eyelids✎

DISORDERS OF THE GLOBE OF THE EYE

- KERATITIS
- CORNEAL ABRASION OR ULCER
- SCLERITIS
- CATARACT
- GLAUCOMA
- MACULAR DEGENERATION
- DIABETIC RETINOPATHY
- RETINAL DETACHMENT
- UVEITIS

KERATITIS

- **MECHANISM**
  - * inflammation and ulceration of the cornea
- **ETIOLOGY**
  - * herpes simplex virus (cold sores)
    * other bacteria & fungi
    * trauma
    * dry air or intense light (welding)

- **SYMPTOMS AND SIGNS**
  - * pain or numbness of the cornea
    * decreased visual acuity
    * irritation
  - * tearing
    * photophobia
    * mild conjunctivitis

- **DIAGNOSIS**
  - * examination of cornea using slit lamp
    * medical history
    * previous upper respiratory tract infection
- **TREATMENT**
  - * eye patch to protect from photophobia

CORNEAL ABRASION OR ULCER

- **ETIOLOGY**
  - * foreign bodies
    * trauma (fingernail, contact lenses)
- **SYMPTOMS AND SIGNS**
  - * pain / redness & tearing
    * something constantly in eye
    * vision impairment

- **DIAGNOSIS**
  - * visual examination
    * fluorescien (stain)
- **TREATMENT**
  - * remove foreign bodies
    * eye wear for protection & promote hearing
    * eye dressing to reduce movement

SCLERITIS

- **MECHANISM**
  - * Inflammation of sclera
- **ETIOLOGY**
  - * rheumatoid arthritis
    * digestive disorders (Crohn's)
- **SYMPTOMS AND SIGNS**
  - * Dull pain
  - * Intense redness
    * loss of vision (posterior sclera inflammation)
    * if untreated can lead to perforation or loss of eye

- **DIAGNOSIS**
  - * ophthalmic examination
    * Blood work to uncover underlying cause
- **TREATMENT**
  - *** MILD**: eye drops (antibiotics)
    *** SEVERE**: immunosupressive drugs
    *** PERFORATION**: surgery

CATARACT

- **MECHANISM**
  - * Gradual deterioration of lens
- **ETIOLOGY**
  - * familial
  - * old age
    * congenital
  - * trauma
    * drug toxicity (high level of steroids)
    * diabetes mellitus

- ***SYMPTOMS AND SIGNS***
  - ** Cloudy / white opaque area of the lens*
    ** reduce visual acuity*
    ** Blurring of vision*
    ** photosensitivity*
- ***DIAGNOSIS***
  - ** Visual examination*
    ** pen light of slit lamp confers the presence of a cataract*
- ***TREATMENT***
  - ** Intracapsular phacoemulsification*
    (involves breakage of cataract then aspiration)
    ** Extracapsular phacoemulsification:*
    (artificial lens replacement)

GLAUCOMA

- *Chronic Open-Angle Glaucoma*
  - *MECHANISM*
    - ** Increased intraocular pressure due to a malfunction in eyes aqueous humor drainage system - can lead to optic nerve damage*
  - *ETIOLOGY*
    - ** trauma*
      ** overuse of steriods*

- ***SYMPTOMS AND SIGNS***
  - ** Gradual loss of peripheral vision.*
    ** If untreated - eventually complete vision loss*
- ***DIAGNOSIS***
  - ** ophthalmic examination*
    ** tonometry (pressure measure)*
- ***TREATMENT***
  - ** Medication that helps decrease aqueous humor production or opens drainage system*
    ** laser to open drainage*
    ** surgery (bypass)*

- *Acute Angle-Closure Glaucoma*
  - *MECHANISM*
    - ** complete blockage of aqueous humor drainage system*
  - *ETIOLOGY*
    - ** trauma*

- *SYMPTOMS AND SIGNS*
  - ** Blurred vision*
  - ** severe eye pain*
    ** redness of the eye*
  - ** nausea & vomiting*
    ** photophobia (sees "halo" around light)*
    ** hazy cornea (elevated pressure)*
    ** if untreated --> blindness*
- *DIAGNOSIS*
  - ** goniolens (special lens to view the opening)*
- *TREATMENT*
  - ** LASER IRIDOTOMY (creation of a hole in the iris between the anterior and posterior chamber)*
    ** medications to reduce pressure*

MACULAR DEGENERATION

- **MECHANISM**
  - *(The area next to optic disc that defines fine details at the center of visual field = macula)*
    ** not enough blood supply to area (disappearance of central vision due to deterioration of pigment layer of retina)*
- **ETIOLOGY**
  - ** age*
  - ** atherosclerosis*
    ** hemorrhage*

- ***SYMPTOMS AND SIGNS***
  - ** Fine detailed vision is impaired*
    ** Sharp vision deterioration (reading)*
    ** peripheral vision is not affected*
    ** loss of central vision*
- ***DIAGNOSIS***
  - ** Ophthalmoscopy*
    ** fluorescein angiography*
    ** patient history*

- ***TREATMENT***
  - ** no known cure*
    ** laser photocoagulation*
    ** increase zinc in diet*
    ** strong magnifying glasses*

DIABETIC RETINOPATHY

- **MECHANISM**
  - * constriction of ocular blood vessels & leakage of blood into retina (microaneurysms, neovascularization = new blood vessels)
    * leakage of blood into vitreous humor
    * scar tissue
- **ETIOLOGY**
  - diabetics with uncontrolled glucose levels

- ***SYMPTOMS AND SIGNS***
  - ** impaired sharp vision*
    ** blurred vision*
    ** could lead to permanent blindness*
- ***DIAGNOSIS***
  - ** Ophthalmoscopy*
- ***TREATMENT***
  - ** Laser photocoagulation*
    ** vitrectomy*

RETINAL DETACHMENT

- **MECHANISM**
  - * elevation & detachment of the retina from the choriod (partial or complete)
- **ETIOLOGY**
  - * Near sightedness (myopia)
    * trauma
- **SYMPTOMS AND SIGNS**
  - * visual floaters
  - * light flashes
    * dark/opaque shadow extending form periphery inward from lower field to upper
    * If central retina is involved, could lead to blindness

- ***DIAGNOSIS***
  - ** Ophthalmoscopy*
- ***TREATMENT***
  - ** Photocoagulation (laser)*
    ** cryotherapy*

UVEITIS

- MECHANISM
  - * Inflammation of uveal tract (iris, ciliary body, choriod)
- ETIOLOGY
  - * autoimmune
    * infections (syphilis, tuberculosis, toxoplasmosis, histoplasmosis)
    * unknown etiology
- SYMPTOMS AND SIGNS
  - * unilateral / bilateral
    * pain
  - * photophobia
    * blurred vision
  - * redness
    * pupillary constriction

- *DIAGNOSIS*
  - * complete visual examination
    * skin test for TB, toxoplasmosis, histoplasmosis
    * blood test
- *TREATMENT*
  - * treat underlying disease if known
    * cycloplegics and steroids

EXOPHTHALMOS

- MECHANISM
  - * Edema of the soft tissue that lines bony orbit of eye
- ETIOLOGY
  - * hyperthyroidism (bilateral)
    * hemorrhage or inflammation (unilateral)
- SYMPTOMS AND SIGNS
  - * protrusion of eye balls
    * dizziness
  - * double vision
    * restricted eye movement
    * seriously blurred vision

- ***DIAGNOSIS***
  - ** ophthalmic examination*
    ** blood work*
  - ** x ray / CT*
    ** echography*
- ***TREATMENT***
  - ** treat underlying disorder (thyroid)*
    ** surgery*
    ** steroids (control edema)*